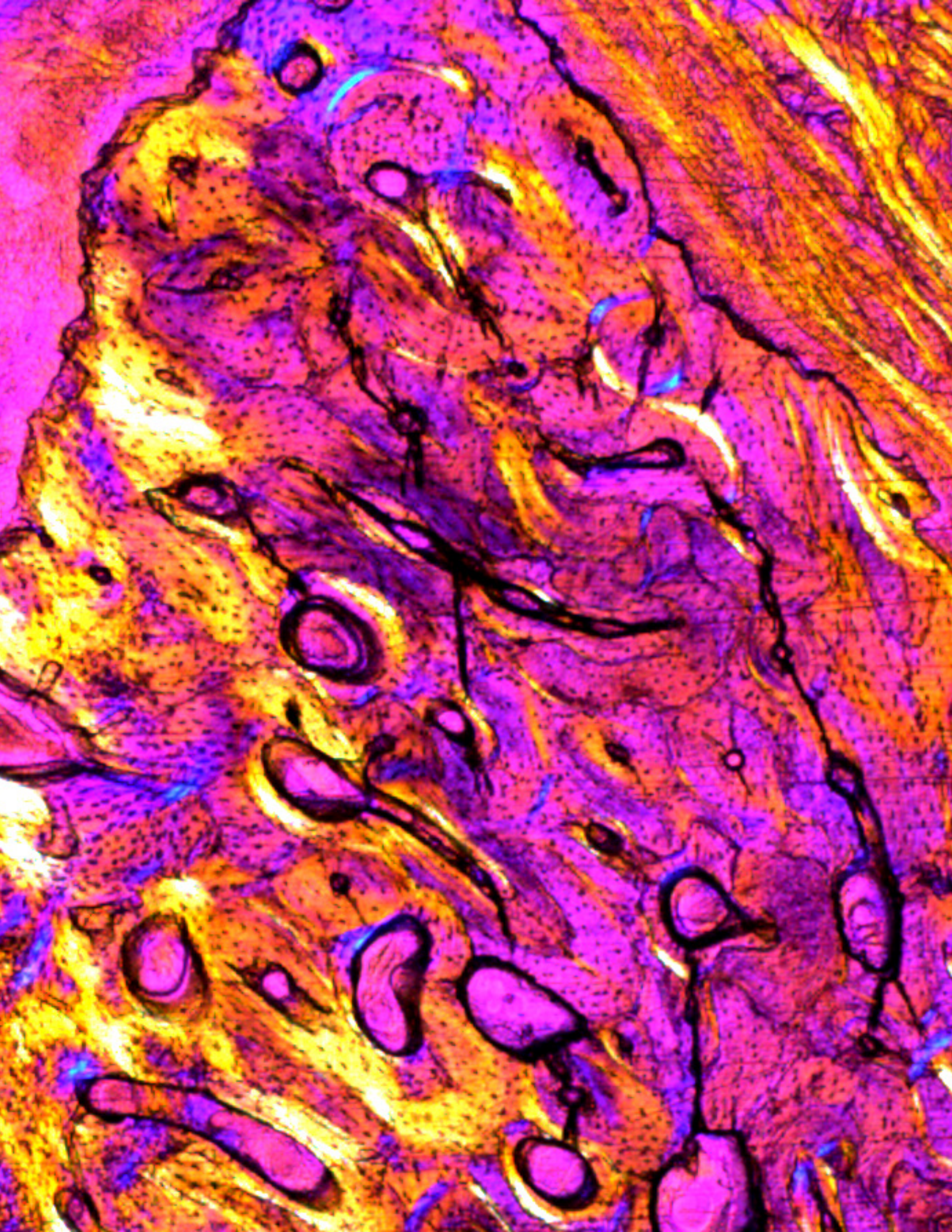


Clinical fundamentals and scientific evidence behind the Neodent® Grand Morse® implant system.

A literature review



Page 01	Introduction
Page 02	Primary stability and immediate protocols
Page 04	Surface roughness and topography
Page 07	Morse taper connection and platform switch
Page 09	Subcrestal implant positioning
Page 10	Abutment selection and biological distance
Page 11	Key clinical data
Page 15	References

INTRODUCTION

Natural, durable, functional and faster results are nowadays necessities that make the difference in the daily practice of a dental implant office. Dental implantology started to be used in humans in 1965 by Prof. Brånemark and colleagues^{1,2}. At this time conventional implant loading procedures were described according to protocols that had to be followed. Since the first descriptions of immediate loading procedures in the 1990s, the technique changed, resulting in fewer clinical steps with the implant and prosthesis beginning to be placed at the same time^{3,4,5}, without significantly affecting the failure rates.

After that time, implants began to be placed right after tooth extraction with high success rates^{6,7}. Consequently, implants, abutments, grafts and restorations started to be placed in the fresh socket in one single clinical step^{6,7,8,9}. This treatment concept perfectly matched the patient's expectations, as temporary tooth- and mucosa-supported restorations have clinical limitations and low acceptance due to discomfort. Nevertheless, studies suggest that esthetic outcomes might be better when implants and restorations are placed just after tooth extraction^{8,9,10}. Figure 01 illustrates the different timing and types of immediate treatments with oral implants.

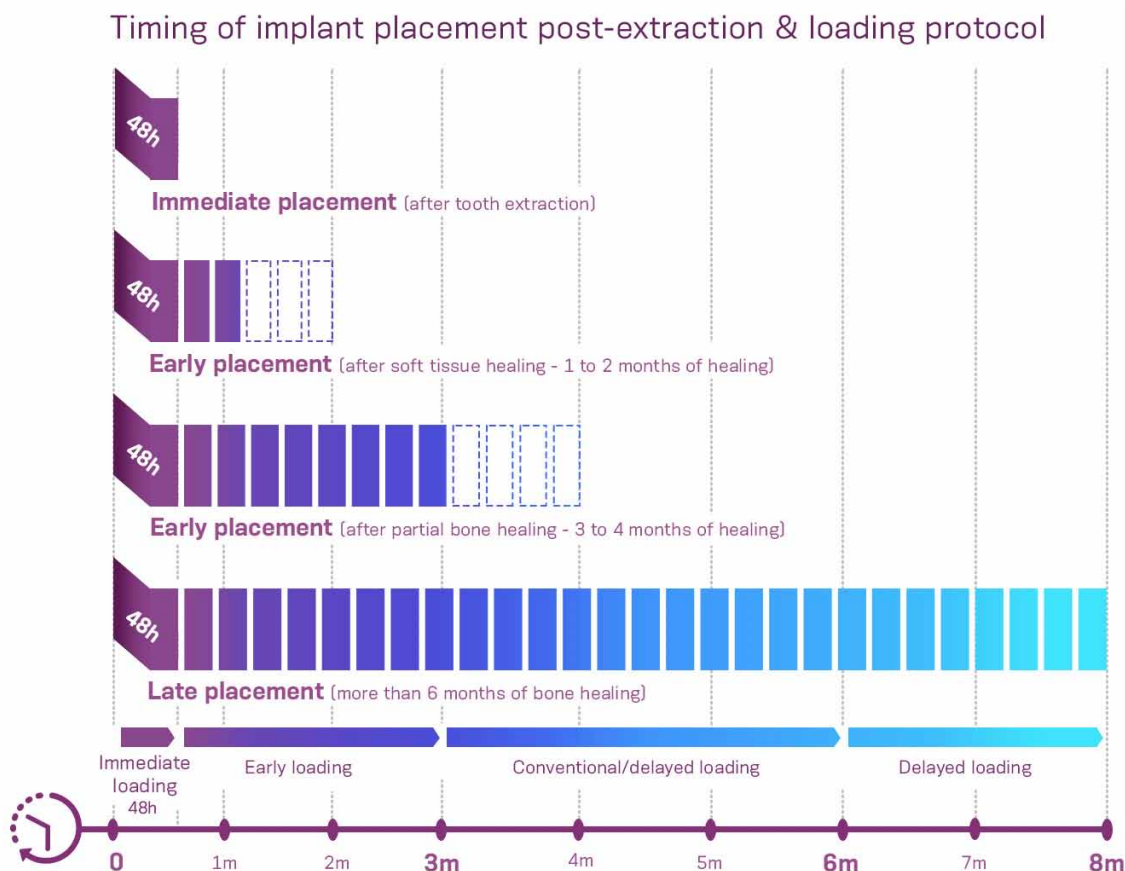


Figure 01. Classification of types of implant placement (post-extraction or late) and loading protocols.

The Grand Morse® implant system has been developed based on these clinical requirements, using clinically proven concepts. The aim of this literature review is to describe and explain the rationale for the main design features of this implant system.

PRIMARY STABILITY AND IMMEDIATE PROTOCOLS

The success of osseointegration relies on two phenomena described in the literature as primary or mechanical stability; and secondary or biological stability¹¹⁻¹³. Primary stability refers to the mechanical resistance of an implant at the time of placement¹⁴, so initial bone to implant contact (BIC) determines its value. Primary stability is a mechanical characteristic established by the contact between bone and the implant threads. The drilling protocol before implant placement is also determinant for the establishment of primary stability. Always local biology and physiology should be respected during this procedure.^{11,12}

Immediate protocols rely mainly on one important characteristic: mechanical stability. Implants under immediate loading should achieve minimum values of primary stability, bearing in mind that osseointegration is equivalent to the healing of a fracture as both start with a damage to an intact bone, an immune response, re-vascularization and the recruitment of mesenchymal cells^{1,15-18}. One way to measure primary stability is known as the "screw test, where a manual surgical wrench is used to measure the final torque of an implant after its placement¹⁹.

Implant macrodesigns are developed to promote higher primary stability. "Square-shaped" threads result in higher bone compression, while "V-shaped" threads facilitate bone removal during implant placement, which has been shown in a pre clinical study²⁰ (Figure 02). Tapered implant designs also result in higher stabilization values when compared to cylindrical or parallel wall designs, as suggested in an in vitro study with data presented in Figure 03.²¹ Based on these principles the Helix[®] implant was designed with progressive dynamic thread from trapezoidal on a coronal part to V-shaped threads on the apex combined full dual tapered body design and a hybrid outer contour: cylindrical on coronal area and conical on the apical part, making this implant compatible for undersized osteotomies and compacting bone in the coronal area. Figure 04 represents the threads and characteristics of the Helix[®] implant.

	V-Thread	Square Thread
Reverse torque value (N= 36 implants)	15.58 ± 6.07*	23.17 ± 9.68*
Percentage of BIC (N= 69 implants)	65.46 ± 9.64*	74.37 ± 8.63*

**Statistical significance (P<0.05) when comparing square thread to V-thread.*

Figure 02. Reverse torque removal values (N.cm) and percentage of bone-to-implant contact (BIC) (n = 12 rabbits). Data extracted from: Steigenga J, Al-Shammari K, Misch C, Nociti FH Jr, Wang HL. Effects of implant thread geometry on percentage of osseointegration and resistance to reverse torque in the tibia of rabbits. J Periodontol. 2004;75(9):1233-41.

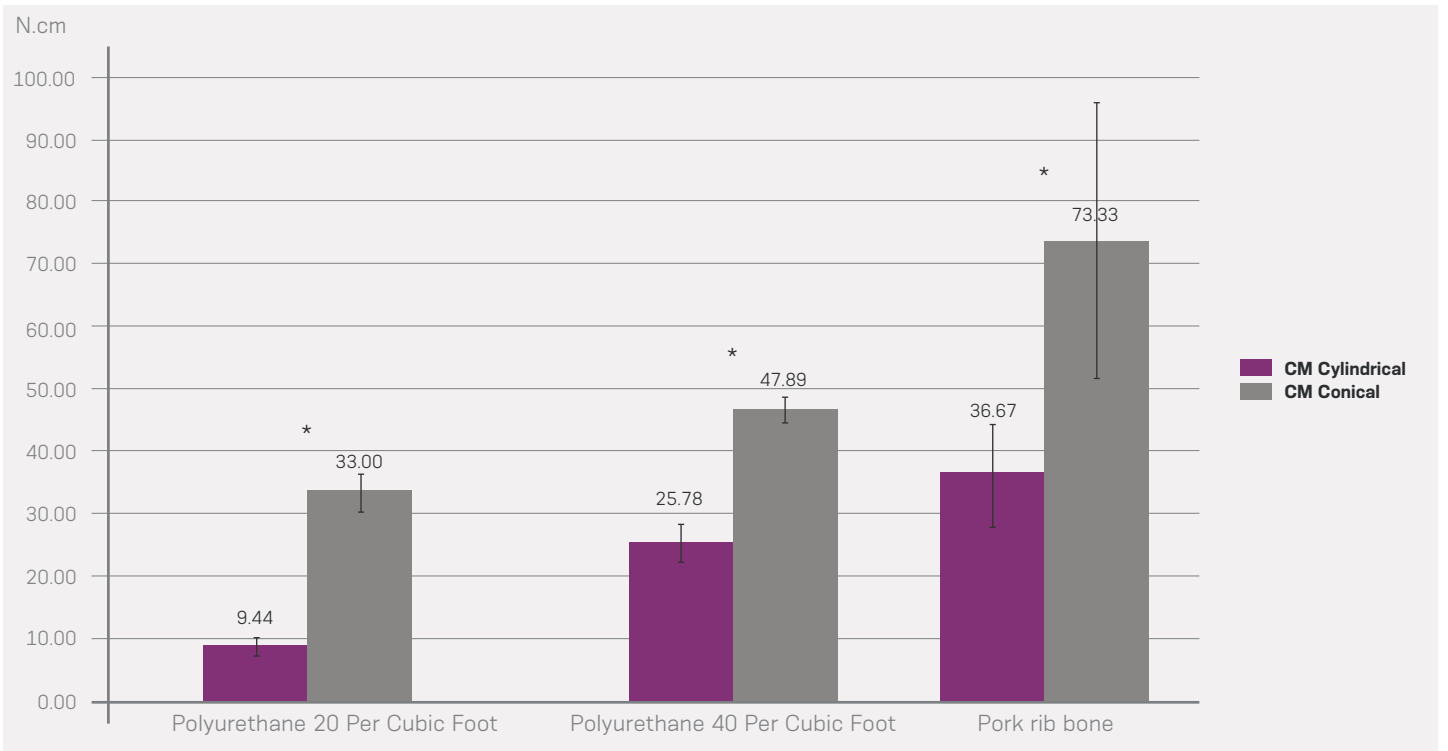


Figure 03. Mean and standard deviation of insertion torque (N.cm) of the implants inserted in different types of substrates. (*) Represents statistical differences. Data extracted from: Valente ML, de Castro DT, Shimano AC, Lepri CP, dos Reis AC. Analysis of the influence of implant shape on primary stability using the correlation of multiple methods. Clin Oral Investig. 2015;19(8):1861-6.



Figure 04. Grand Morse® Helix® implant features a hybrid threads: trapezoidal and V-shaped, combined full dual tapered body design with a hybrid outer contour.

SURFACE ROUGHNESS AND TOPOGRAPHY

The treatment success with dental implants is directly related to osseointegration, which is a structural connection between bone and the implant surface under functional occlusal loading^{2,22}. Bone deposition over the implant surface depends directly on the interactions between cells and the implant (fixture alloy, roughness, thread design, osteotomy, patient's local and general health, loading protocol, etc.)²³. Then, secondary stability relies on the capacity of an implant to remain stable with live peri-implant tissue deposition and regeneration post-osseointegration¹³. Nowadays there exists great interest in the implant surface, which can bring the loading protocol forward to an earlier stage, as it can promote faster osseointegration and lead to secondary stability sooner²⁴⁻²⁶. At the same time, many studies have been evaluating the effects of implant surface modification on the microenvironment created between the bone and the implant during placement and osseointegration. Thus, some surface modifications are methods that can accelerate and enhance the quality of osseointegration, resulting in greater bone deposition and shortening the osseointegration period²⁴⁻²⁹.

With the evolution of dental implantology, changes in the original surface were suggested, to optimize osseointegration^{30,31}. Brunette and colleagues showed that bone deposition occurs in both smooth or rough-treated surfaces, suggesting that roughness may not act as a determinant factor in osseointegration, but definitely enhances bone deposition³². So, different surface treatments have been developed, with distinct levels of roughness. Studies reveal that implant surface characteristics directly influence cell behavior, especially when it comes to adhesion, proliferation, morphometric and functional changes^{25,32}. So topography, chemical composition, surface charge and wettability have been described as the main properties of the implant surface²⁵.

The Neodent Neoporos surface has a macro-topography of 20-40 μm ; micro-topography of 2-4 μm ; and an arithmetic mean height of 1.3 μm , a scientifically proven roughness³⁴ (Figure 05). This surface topography result in implants with high clinical success rates, even reaching 99.7%³⁵⁻⁴⁰, as described in the section "Key clinical data" in the end of the present literature review. The hydrophilic surface Acqua® has been designed for immediate access of blood to the implant surface, which may result in faster increase of resonance frequency (ISQ), 2.24 times faster than implants with hydrophobic surfaces³⁹.


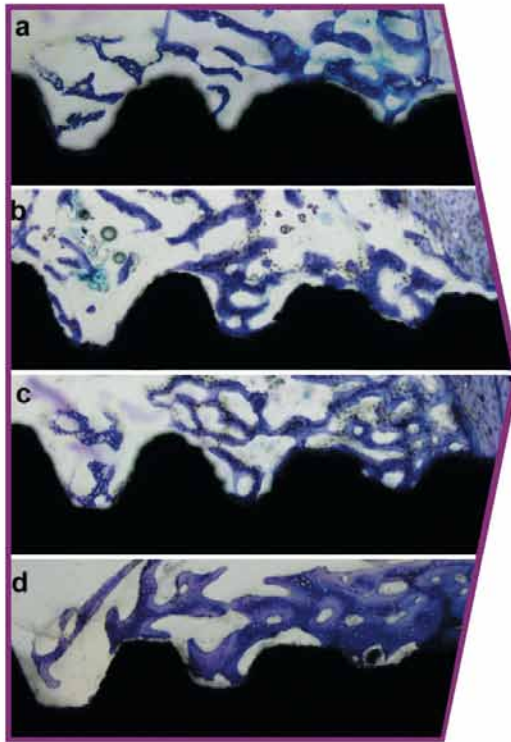
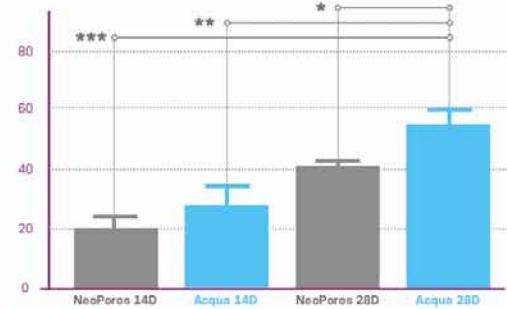


Figure 05. NeoPoros (a and c) and Acqua (b and d) scanning electron microscopy showing the roughness of the Grand Morse® NeoPoros and Acqua implant surfaces (no difference between the groups was observed), with a macro-topography of 20-40 µm and micro-topography of 2-4 µm. A and B (original magnification 1000X) and C and D (original magnification 3000X). Image taken from: Sartoretto SC, Alves AT, Resende RF, Calasans-Maia J, Granjeiro JM, Calasans-Maia MD. Early osseointegration driven by the surface chemistry and wettability of dental implants. *J Appl Oral Sci.* 2015;23(3):279-87.

The initial contact of a titanium implant surface occurs the moment an implant is placed, because of the presence of blood clotting. Then, an initial interaction takes place involving platelets and fibrinogen at the implant surface with its oxide layer. After this, osteogenic cell adhesion takes place, resulting in the formation of a fibrin network. Hence osteogenic cell adhesion occurs in a titanium oxide layer modified by blood cells. These osteogenic cells synthesize an extracellular matrix and a mineral phase. The extracellular matrix induces further cell adhesions. Subsequently uncalcified bone substance at the bone-implant interface is converted into mineralized trabecular bone^{41,43}. These biological mechanisms of bone deposition are influenced by different implant characteristics, including chemical composition and implant topography^{23,25,44} which has been observed in preclinical studies with the Neodent Acqua surface^{34,45,46}. Figure 06 shows the results from a preclinical study of NeoPoros versus Acqua implants³⁴.



A - BAFO (%)



B - BIC (%)

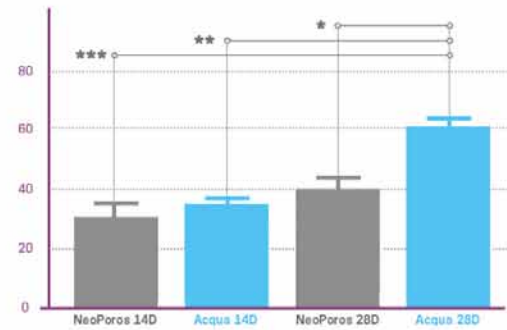


Figure 06: Photomicrographs of NeoPoros at 14 days (a) and 28 days (b) and Acqua at 14 days (c) and 28 days (d). Observe the presence of new bone formation between the threads and the contact between bone and both implant groups. Acqua at 28 days had more, and more compact, trabecular bone than NeoPoros at the same time point. (A) Bone area fraction occupied (BAFO) of the total region between the threads and (B) mean BIC as a percentage of the total implant area shown as mean percentages \pm standard deviation (* $p < 0.05$; ** $p < 0.01$; *** $p < 0.001$). Image taken from: Sartoretto SC, Alves AT, Resende RF, Calasans-Maia J, Granjeiro JM, Calasans-Maia MD. Early osseointegration driven by the surface chemistry and wettability of dental implants. *J Appl Oral Sci.* 2015;23(3):279-87.

MORSE TAPER CONNECTION AND PLATFORM SWITCH

Researchers in the field of dental implantology have been largely studying the implant/abutment connection, as this part of the implant system has important influences on clinical outcomes, due to its mechanical and biological impact⁴⁶⁻⁵¹. Morse taper implant/abutment connections have a mechanical design that results in less bone remodeling and high mechanical strength^{46-51,53,54}, with higher resistance than other internal connection⁵⁴ (Figure 07). This type of connection was invented by Stephen A. Morse in 1864 as a way of joining two machine components by the principle of a “cone within a cone”, where both the male and female connections are tapered to the same degree^{54,55}. Morse’s original Morse taper had a small angle of 2°. The concept has been widely used in engineering, but was adapted for orthopedic use in the 1970s, most commonly with taper angles of between 5 and 18°. It has subsequently been successfully employed in dental implants, many with either an 8° or 16° angle, due to its numerous advantages in this setting. A Morse taper connection depends on the internal angle of the pieces in contact and friction between them^{47,48,54,55} (Figure 08). The Grand Morse® connection has a full angle of 16° respecting this concept. Figure 09 presents an example of a clinical case with 13 months of follow-up and the usual bone maintenance observed for Morse taper implants.

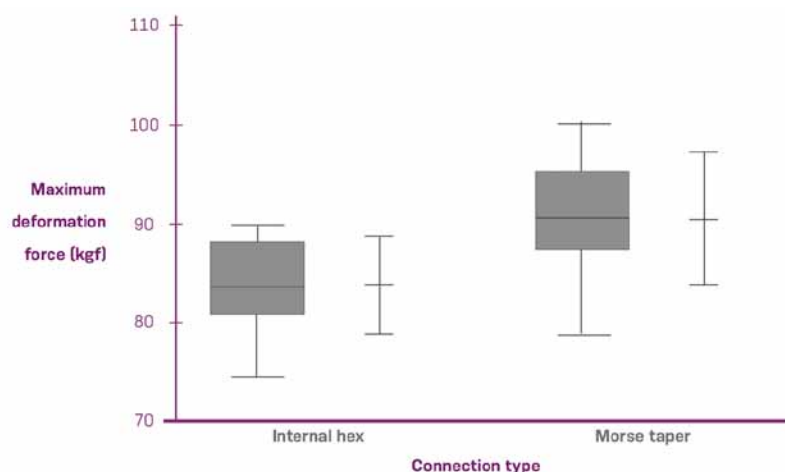


Figure 07. Maximum deformation force values for the internal hex and the Morse taper systems. Image adapted from: Coppedè AR, Bersani E, de Mattos Mda G, Rodrigues RC, Sartori IA, Ribeiro RF. Fracture resistance of the implant-abutment connection in implants with internal hex and internal conical connections under oblique compressive loading: an in vitro study. *Int J Prosthodont*;2009;22(3):283-6..53

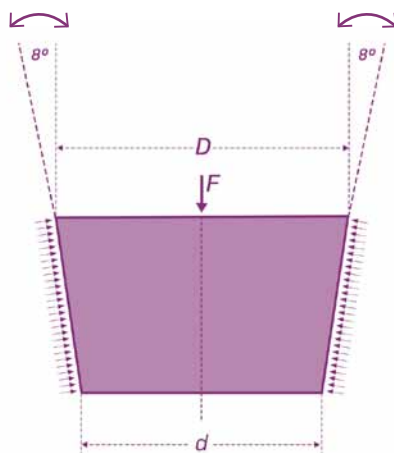


Figure 08. Image adapted from Edward and Charles⁵³ showing that a true Morse taper connection relies on the internal angle of the pieces and the friction between them. In the Grand Morse® connection, a 16° angle and the friction between the titanium pieces (implants and abutment) is more than enough to classify it as a Morse cone connection.

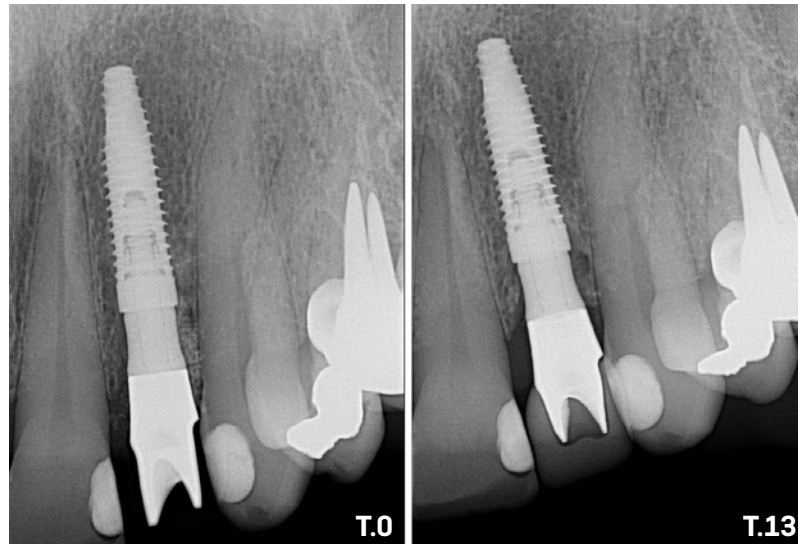


Figure 09. Periapical Xray of a Grand Morse® implant with 13 months of follow up.

Another important feature incorporated into the Grand Morse® implants is platform switching (Figure 10). In the literature, platform-switched implants result in fewer changes in marginal bone level over time⁵⁴⁻⁵⁸. This platform mismatching was created to enhance bone stability as it has beneficial effects on the peri-implant marginal bone⁵⁶⁻⁶⁰. Additionally, combining a Morse taper with a platform switch supports to create a favorable peri-implant bone maintenance, but also because of the minimized abutments micromovements at the connection level as well as a bacterial seal in this area due to the friction between parts^{47,48,54,55} (Figure 10).

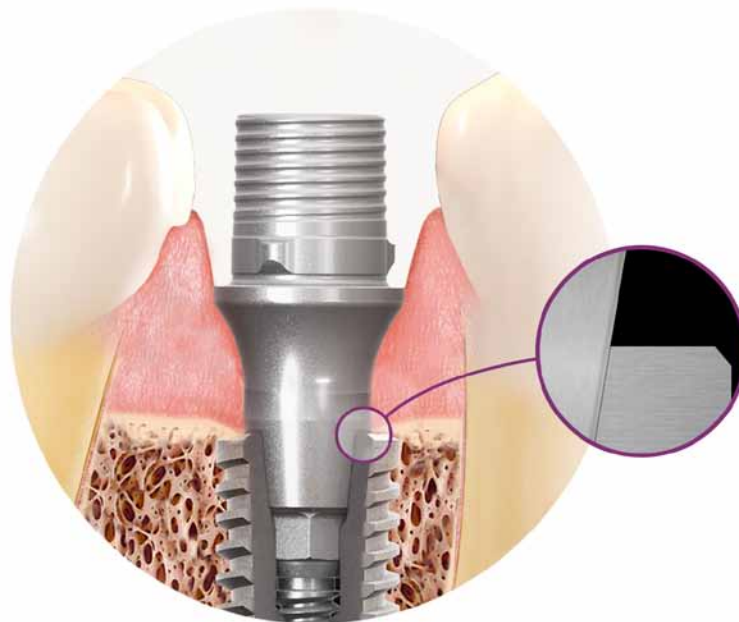


Figure 10. Concave-shaped abutment with a platform switching design (abutment/implant horizontal mismatching) and a Morse taper connection.

SUBCRESTAL IMPLANT POSITIONING

Crestal bone remodeling is a phenomenon that arises due to different hypotheses, including surgical trauma, occlusal overload, peri-implantitis, microgap, biologic width, and implant crest module⁶¹. From a mechanical point of view, Morse taper implants placed 1-2mm subcrestally is designed to shift the peak stresses from the bone crest (if bone level) to the trabecular bone below⁶². On the other hand, the re-establishment of the biologic width naturally occurs when an implant is placed⁶³. If the final implant position is subcrestal, it results in longer abutment heights, thereby leaving a space for better bone margin position. As described, longer abutments are necessary when implants are subcrestally positioned and one clinical study has suggested that longer abutments may be less likely to lead to crestal bone loss over time⁶⁵. One reason for this might be the tighter mucosal attachment to the smooth surface of the titanium abutment and thus builds a natural biological barrier. Studies show that subcrestal positioning of implants with Morse taper connections favors marginal bone maintenance^{46,48,49,65-67} (Figure 11). Since this connection results in maximizing bacterial seal, reducing micromovements and platform switching, it can be concluded that Morse taper implants can be placed deeper inside the bone, resulting in longer abutment heights, and a longer, stable mucosal seal/biologic peri-implant width, thereby reducing the esthetic and functional risks of any implant dehiscence and promoting a better environment for marginal bone maintenance.

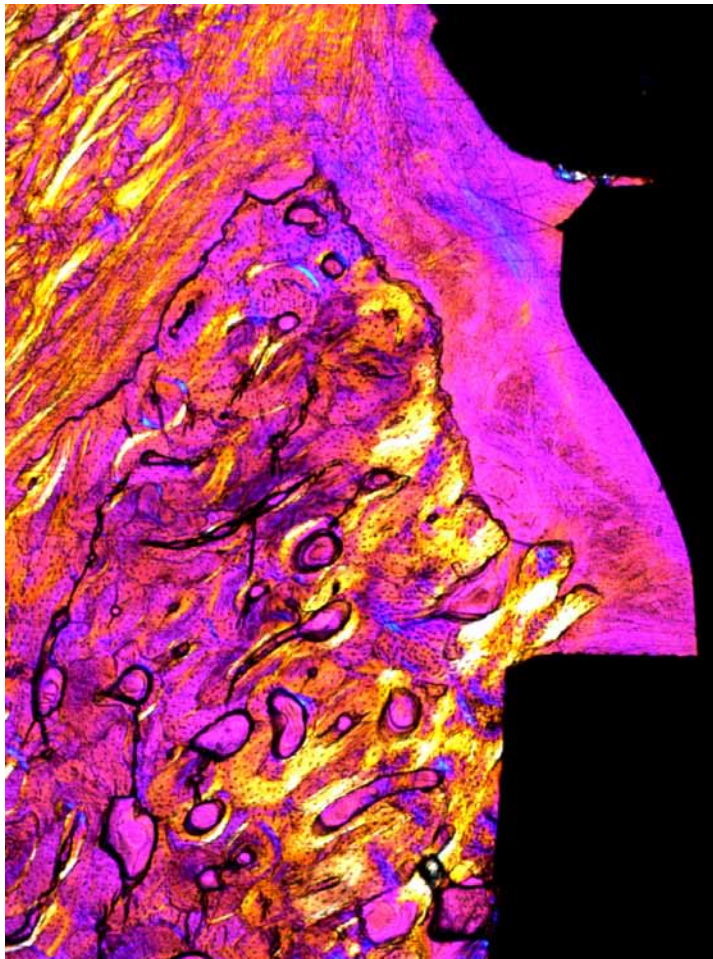


Figure 11. Histomorphometrical slice of a Morse taper implant subcrestally positioned (image kindly shared by Prof. Carlos Araújo, São Paulo University, Bauru, Brazil) showing bone maintenance, biologic width and soft tissue O-ring.

ABUTMENT SELECTION AND BIOLOGICAL DISTANCE

The margin of a restoration is always a 'weak area' between teeth and implants, as it can promote bacterial colonization and inflammation. With dental implants, abutments can be cemented or screw-retained. Cements are cytotoxic and any excess could result in implant failure⁶⁸, while screw-retained restorations result in bacterial colonization in the inner parts of implants, abutments and crowns^{69,70}. So, whatever the margin, it should achieve a minimum distance from the bone as soft tissue structures react better to this negative influence. The peri-implant biologic width contains cells and proteins capable of creating a soft tissue O-ring seal protecting the hard tissue^{63,71-73}, especially when using concave-shaped abutments^{71,75}, as can be seen at Figure 09. The ideal abutment margin has to be properly planned, particularly when placing implants below the bone level since the margin gets closer to the bone. The margin should be at least 1.5-2.0mm from the bone crest as illustrated in Figure 12, so the transmucosal height of an abutment has to be determined based on the quantity of mucosa exists above the bone.⁷⁵

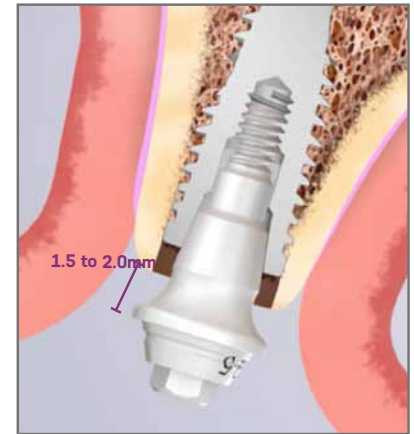

Figure 12. Abutment margin with a safe distance from the bone crest (minimum 1.5mm).

Ideally, abutments should be chosen by a clinician based on the guidelines described above and preferably they should be as definitive as possible in order to avoid bone remodeling. Another important aspect in abutment selection is to prevent any changing of components after healing. Animal studies^{75,76} indicated the disconnecting and then reconnecting the abutment compromised the mucosa/implant barrier and resulted in a more "apical" positioning of connective and hard tissue. Additional marginal bone resorption was observed at sites where the abutment was handled as a result of tissue reactions initiated to establish a proper peri-implant biologic width^{76,77}. These findings were also observed in clinical studies, suggesting that the non-removal of an abutment placed at the time of implant surgery (immediate loading) or later (during the second surgery) results in a reduction of bone remodeling around implants⁷⁹⁻⁸², especially Morse taper implants positioned subcrestally^{79,81}. Figure 13 presents data from a clinical study that conducted a comparison between patients submitted to "one abutment at one time" and a group with regular implant level workflow, that used temporary abutments.

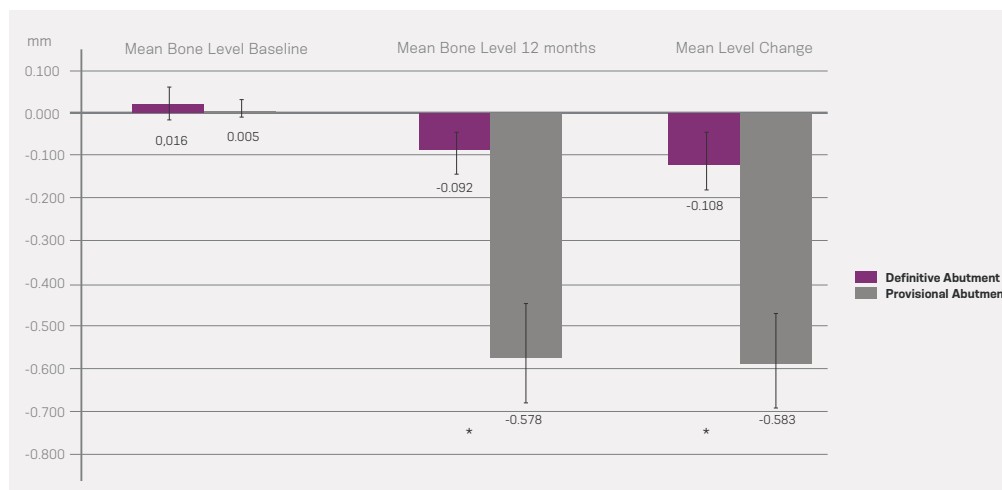


Figure 13. Mean radiographic peri-implant bone resorption in the two groups of study at different times. There were significant differences between: Mean bone level baseline Definitive Abutment (DA) versus Mean bone level 12 months DA; Mean bone level 12 months Provisional Abutment (PA) versus Mean bone level 12 months DA; Mean bone level baseline PA versus Mean bone level 12 months PA ($P < 0.0001$). Data extracted from: Grandi T, Guazzi P, Samarani R, Maghaireh H, Grandi G. One abutment-one time versus a provisional abutment in immediately loaded post-extractive single implants: a 1-year follow-up of a multicentre randomised controlled trial. *Eur J Oral Implantol.* 2014;7(2):141-9.

KEY CLINICAL DATA

 **“Retrospective analysis of 2,244 implants and the importance of follow-up in implantology.”**
(Sartori IAM, Latenek RT, Budel LA, Thomé G, Bernardes SR, Tioossi R. IDR. 2014;2(6):555-565.)³⁶

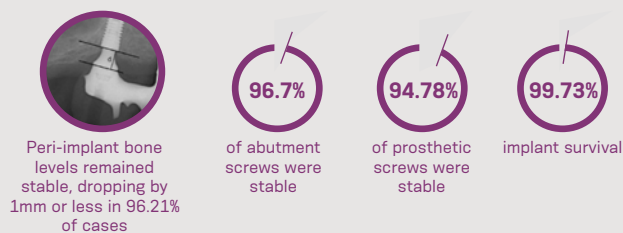
Aims

A retrospective clinical analysis evaluated the clinical behavior of the prosthetic restorations, screw joint stability, peri-implant bone level and soft tissues, implant survival rate and patient satisfaction.

Materials & Methods



Results



Conclusion

Continuous follow-up of patients with implant restorations provides essential information on the behavior of implants and prosthetic components, enabling the early intervention in minor prosthetic complications (e.g. screw loosening) to avoid future major complications (e.g. implant failure).



“Marginal Bone Loss in Implants Placed in the Maxillary Sinus Grafted With Anorganic Bovine Bone: A Prospective Clinical and Radiographic Study.”

(Dinato TR, Grossi ML, Teixeira ER, Dinato JC, Sczepanik FS, Gehrke SA. J Periodontol. 2016 Aug;87(8):880-7.)⁵⁰

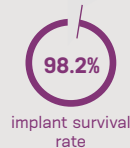
Background

Sinus elevation is a reliable and often-used technique. Success of implants placed in such situations, even with bone substitutes alone, prompted the authors of this study to strive for bone loss close to zero and research variables that cause higher or lower rates of resorption. The objective of this study is to evaluate survival rates and marginal bone loss (MBL) around implants placed in sites treated with maxillary sinus augmentation using anorganic bovine bone (ABB), and identify surgical and prosthetic prognostic variables.

Materials & Methods



Results



75.9% of mesial sites and 83.4% of distal sites showed <1 mm of marginal bone loss, whereas 35.2% of mesial sites and 37% of distal sites exhibited NO bone loss.

Conclusion

Within the limitations of the present study, it was concluded that maxillary sinus elevation with 100% ABB gives predictable results, and that flapless surgery results in less MBL compared with traditional open-flap surgery.

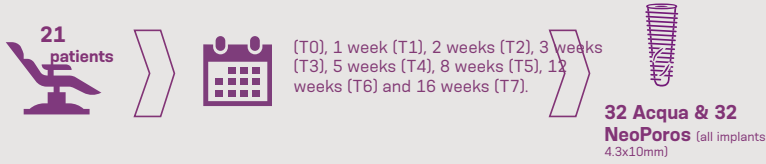
“Resonance frequency analysis of dental implants placed at the posterior maxilla varying the surface treatment only: A randomized clinical trial.”

(Novellino M, Sesma N, Zanardi PR, Dalva CL. Clin Implant Dent Relat Res 2017.)³⁹

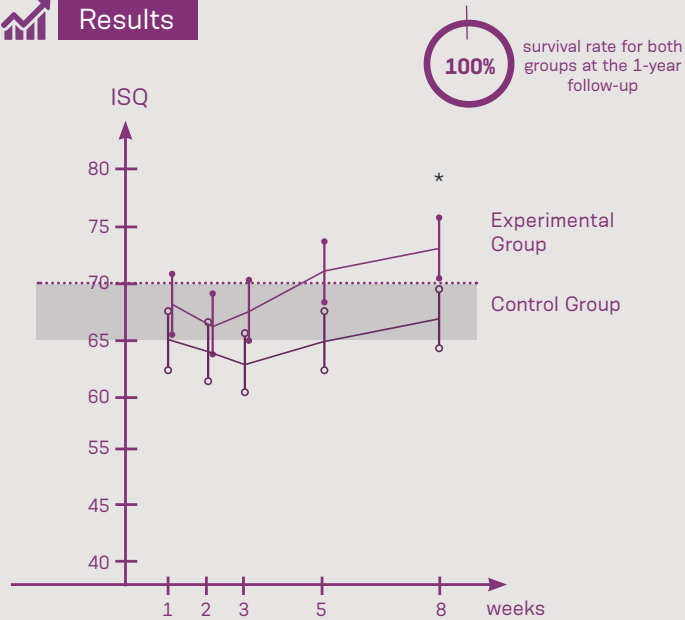
Aims

To evaluate the implant stability quotient (ISQ) of implants with similar designs and two surface treatments sandblasted acid-etched (SAE) and hydrophilic SAE, during the initial 16 weeks of healing.

Materials & Methods



Results



Mean ISQ values and confidence interval of Acqua and NeoPoros. Acqua presented higher ISQ values than the control group from 8 to 16 weeks.

Conclusion

The current study suggests that Acqua implants integrate faster than NeoPoros. The stability gain of the test group was 2.24 times faster than the control group after 5 weeks of evaluation in the posterior region of the edentulous maxillae.



“Retrospective, cross-sectional study on immediately loaded implant-supported mandibular fixed complete-arch prostheses fabricated with the passive fit cementation technique.”

(Able FB, de Mattias Sartori IA, Thomé G, Moreira Melo AC. *J Prosthet Dent.* 2018;119(1):60-66.)⁴⁰

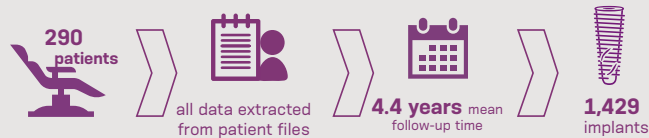

Purpose

The purpose of this cross-sectional study of immediately loaded mandibular fixed complete-arch dental prostheses was to evaluate the survival and success rates of prostheses, the survival rates of dental implants, the occurrence of complications in the prostheses and implants, participant satisfaction, and the association between cantilever length and prosthesis complications.



Materials & Methods



Results



Conclusion

Implant-supported mandibular fixed complete-arch dental prostheses fabricated with a passive fit technique provide successful treatment for patients with edentulism. The success and survival rates of implants and prostheses were high. Only straightforward complications were observed. Cantilever length was not associated with complications.

REFERENCES

1. Brånemark PI et al. Osseointegrated implants in the treatment of the edentulous jaw. Experience from a 10-year period. *Scand J Plast Reconstr Surg Suppl.* 1977;16:1-132.
2. Adell R, Lekholm U, Rockler B, Brånemark PI. 15-year study of osseointegrated implants in the treatment of the edentulous jaw. *Int J Oral Surg.* 1981;10(6):387-416.
3. Schnitman PA, Wohrle PS, Rubenstein JE. Immediate fixed interim prostheses supported by two-stage threaded implants: methodology and results. *J Oral Implantol.* 1990;16(2):96-105.
4. Schnitman PA et al. Ten-year results for Brånemark implants immediately loaded with fixed prostheses at implant placement. *Int J Oral Maxillofac Implants.* 1997;12(4):495-503.
5. Chrcanovic BR, Albrektsson T, Wennerberg A. Immediate nonfunctional versus immediate functional loading and dental implant failure rates: a systematic review and meta-analysis. *J Dent.* 2014;42(9):1052-9.
6. Chrcanovic BR, Albrektsson T, Wennerberg A. Dental implants inserted in fresh extraction sockets versus healed sites: a systematic review and meta-analysis. *J Dent.* 2015;43(1):16-41.
7. Enríquez-Sacristán C, Barona-Dorado C, Calvo-Guirado JL, Leco-Berrocal I, Martínez-González JM. Immediate post-extraction implants subject to immediate loading: a meta-analytic study. *Med Oral Patol Oral Cir Bucal.* 2011;16(7):e919-24.
8. Arlin ML. Immediate placement of osseointegrated dental implants into extraction sockets: advantages and case reports. *Oral Health.* 1992;82(7):19-20, 23-4, 26.
9. Werbitz MJ, Goldberg PV. The immediate implant: bone preservation and bone regeneration. *Int J Periodontics Restorative Dent.* 1992;12(3):206-17.
10. Esposito M, Grusovin MG, Polyzos IP, Felice P, Worthington HV. Interventions for replacing missing teeth: dental implants in fresh extraction sockets (immediate, immediate-delayed and delayed implants). *Cochrane Database Syst Rev.* 2010;(9):CD005968.
11. Skalak R. Biomechanical considerations in osseointegrated prostheses. *J Prosthet Dent.* 1983;49(6):843-8.
12. Buser D, Schenk RK, Steinemann S, Fiorellini JP, Fox CH, Stich H. Influence of surface characteristics on bone integration of titanium implants. A histomorphometric study in miniature pigs. *J Biomed Mater Res.* 1991;25(7):889-902.
13. Cochran DL, Schenk RK, Lussi A, Higginbottom FL, Buser D. Bone response to unloaded and loaded titanium implants with a sandblasted and acid-etched surface: a histometric study in the canine mandible. *J Biomed Mater Res.* 1998;40(1):1-11.
14. Meredith N. Assessment of implant stability as a prognostic determinant. *Int J Prosthodont.* 1998;11(5):491-501.

15. Albrektsson T, Albrektsson B. Osseointegration of bone implants: A review of an alternative mode of fixation, *Acta Orthopaedica Scandinavica*, 1987;(58):5, 567-577.
16. Simmons CA, Meguid SA, Pilliar RM. Mechanical regulation of localized and appositional bone formation around bone-interfacing implants. *J Biomed Mater Res*. 2001;55(1):63-71.
17. Kuzyk PRT, Schemitsch EH. The basic science of peri-implant bone healing. *Indian J Orthop*. 2011; 45(2): 108–115.
18. Colnot C et al. Molecular analysis of healing at a bone-implant interface. *J Dent Res*. 2007;86(9):862-7.
19. Nikellis I, Levi A, Nicolopoulos C. Immediate loading of 190 endosseous dental implants: a prospective observational study of 40 patient treatments with up to 2-year data. *Int J Oral Maxillofac Implants*. 2004;19(1):116-23.
20. Steigenga J, Al-Shammari K, Misch C, Nociti FH Jr, Wang HL. Effects of implant thread geometry on percentage of osseointegration and resistance to reverse torque in the tibia of rabbits. *J Periodontol*. 2004;75(9):1233-41.
21. Valente ML, de Castro DT, Shimano AC, Lepri CP, dos Reis AC. Analysis of the influence of implant shape on primary stability using the correlation of multiple methods. *Clin Oral Investig*. 2015;19(8):1861-6.
22. Brånemark R, Brånemark PI, Rydevik B, Myers RR. Osseointegration in skeletal reconstruction and rehabilitation: a review. *J Rehabil Res Dev*. 2001;38(2):175-81.
23. Palmquist A, Omar OM, Esposito M, Lausmaa J, Thomsen P. Titanium oral implants: surface characteristics, interface biology and clinical outcome. *J R Soc Interface*. 2010;7 Suppl 5:S515-27.
24. Lai HC, Zhuang LF, Zhang ZY, Wieland M, Liu X. Bone apposition around two different sandblasted, large-grit and acid-etched implant surfaces at sites with coronal circumferential defects: an experimental study in dogs. *Clin Oral Implants Res*. 2009;20:247-53.
25. Wennerberg A, Albrektsson T. Effects of titanium surface topography on bone integration: a systematic review. *Clin Oral Implants Res*. 2009;20 Suppl 4:172-84.
26. Lang NP, Salvi GE, Huynh-Ba G, Ivanovski S, Donos N, Bosshardt DD. Early osseointegration to hydrophilic and hydrophobic implant surfaces in humans. *Clin Oral Implants Res*. 2011;22:349-56.
27. Stanford CM. Surface modification of biomedical and dental implants and the processes of inflammation, wound healing and bone formation. *Int J Mol Sci*. 2010;11:354-69.
28. Buser D, Broggin N, Wieland M, Schenk RK, Denzer AJ, Cochran DL, Hoffmann B, Lussi A, Steinemann SG. Enhanced bone apposition to a chemically modified SLA titanium surface. *J Dent Res*. 2004;83:529-33.

29. Cochran DL, Buser D, ten Bruggenkate CM, Weingart D, Taylor TM, Bernard JP, Peters F, Simpson JP. The use of reduced healing times on ITI implants with a sandblasted and acid-etched (SLA) surface: early results from clinical trials on ITI SLA implants. *Clin Oral Implants Res.* 2002;13:144-53.
30. Novaes AB Jr, de Souza SL, de Barros RR, Pereira KK, Iezzi G, Piattelli A. Influence of implant surfaces on osseointegration. *Braz Dent J.* 2010;21:471-81.
31. Gupta A, Dhanraj M, Sivagami G. Status of surface treatment in endosseous implant: a literary overview. *Indian J Dent Res.* 2010;21:433-8.
32. Brunette DM. The effects of implant surface topography on the behavior of cells. *Int J Oral Maxillofac Implants.* 1988;3(4):231-46.
33. Martin JY, Schwartz Z, Hummert TW, Schraub DM, Simpson J, Lankford J Jr, Dean DD, Cochran DL, Boyan BD. Effect of titanium surface roughness on proliferation, differentiation, and protein synthesis of human osteoblast-like cells (MG63). *J Biomed Mater Res.* 1995;29:389-401.
34. Sartoretto SC, Alves AT, Resende RF, Calasans-Maia J, Granjeiro JM, Calasans-Maia MD. Early osseointegration driven by the surface chemistry and wettability of dental implants. *J Appl Oral Sci.* 2015;23(3):279-87.
35. Borges AF, Dias Pereira LA, Thomé G, Melo AC, de Mattias Sartori IA. Prostheses removal for suture removal after immediate load: success of implants. *Clin Implant Dent Relat Res.* 2010;12(3):244-8.
36. Sartori IAM, Latenek RT, Budel LA, Thomé G, Bernardes SR, Tioffi R. Retrospective analysis of 2,244 implants and the importance of follow-up in implantology. *JRD.* 2014;2(6): 555-565.
37. Dias RR, Sehn FP, de Santana Santos T, Silva ER, Chaushu G, Xavier SP. Corticocancellous fresh-frozen allograft bone blocks for augmenting atrophied posterior mandibles in humans. *Clin Oral Implants Res.* 2016;27(1):39-46.
38. Melo LA, Souza MBC, Barbosa GAS, Carreiro ADFP. Peri-Implant Bone Loss of External Hexagon and Morse Taper in Patients Wearing Immediately Loaded Overdentures. *Braz Dent J.* 2017;28(6):694-698.
39. Novellino MM, Sesma N, Zanardi PR, Laganá DC. Resonance frequency analysis of dental implants placed at the posterior maxilla varying the surface treatment only: A randomized clinical trial. *Clin Implant Dent Relat Res.* 2017 Oct;19(5):770-775.
40. Able FB, de Mattias Sartori IA, Thomé G, Moreira Melo AC. Retrospective, cross-sectional study on immediately loaded implant-supported mandibular fixed complete-arch prostheses fabricated with the passive fit cementation technique. *J Prosthet Dent.* 2018;119(1):60-66.
41. Terheyden H, Lang NP, Bierbaum S, Stadlinger B. Osseointegration--communication of cells. *Clin Oral Implants Res.* 2012;23(10):1127-35.

42. Ivanovski S, Hamlet S, Salvi GE, Huynh-Ba G, Bosshardt DD, Lang NP, Donos N. Transcriptional profiling of osseointegration in humans. *Clin Oral Implants Res.* 2011;22(4):373-81.
43. Davies JE. Mechanisms of endosseous integration. *Int J Prosthodont.* 1998;11:391-401.
44. Le Guéhennec L, Soueidan A, Layrolle P, Amouriq Y. Surface treatments of titanium dental implants for rapid osseointegration. *Dent Mater.* 2007;23:844-54.
45. Sartoretto SC, Alves ATNN, Zarranz L, Jorge MZ, Granjeiro JM, Calasans-Maia MD. Hydrophilic surface of Ti6Al4V-ELI alloy improves the early bone apposition of sheep tibia. *Clin Oral Implants Res.* 2017;28(8):893-901.
46. Val JE, Gómez-Moreno G, Ruiz-Linares M, Prados-Frutos JC, Gehrke SA, Calvo-Guirado JL. Effects of Surface Treatment Modification and Implant Design in Implants Placed Crestal and Subcrestally Applying Delayed Loading Protocol. *J Craniofac Surg.* 2017;28(2):552-558.
47. Schmitt CM, Nogueira-Filho G, Tenenbaum HC, Lai JY, Brito C, Döring H, Nonhoff J. Performance of conical abutment (Morse Taper) connection implants: a systematic review. *J Biomed Mater Res A.* 2014;102(2):552-74.
48. Macedo JP, Pereira J, Vahey BR, Henriques B, Benfatti CA, Magini RS, López-López J, Souza JC. Morse taper dental implants and platform switching: The new paradigm in oral implantology. *Eur J Dent.* 2016;10(1):148-54.
49. Castro DS, Araujo MA, Benfatti CA, Araujo C dos R, Piattelli A, Perrotti V, Iezzi G. Comparative histological and histomorphometrical evaluation of marginal bone resorption around external hexagon and Morse cone implants: an experimental study in dogs. *Implant Dent.* 2014;23(3):270-6.
50. Dinato TR, Grossi ML, Teixeira ER, Dinato JC, Sczeganik FS, Gehrke SA. Marginal Bone Loss in Implants Placed in the Maxillary Sinus Grafted With Anorganic Bovine Bone: A Prospective Clinical and Radiographic Study. *J Periodontol.* 2016 Aug;87(8):880-7.
51. Melo LA, Souza MBC, Barbosa GAS, Carreiro ADFP. Peri-Implant Bone Loss of External Hexagon and Morse Taper in Patients Wearing Immediately Loaded Overdentures. *Braz Dent J.* 2017;28(6):694-698.
52. Hernigou P, Queinnec S, Flouzat Lachaniette CH. One hundred and fifty years of history of the Morse taper: from Stephen A. Morse in 1864 to complications related to modularity in hip arthroplasty. *Int Orthop.* 2013;37(10):2081-8.
53. Coppedè AR, Bersani E, de Mattos Mda G, Rodrigues RC, Sartori IA, Ribeiro RF. Fracture resistance of the implant-abutment connection in implants with internal hex and internal conical connections under oblique compressive loading: an in vitro study. *Int J Prosthodont.* 2009;22(3):283-6.
54. Bozkaya D, Müftü S. Mechanics of the taper integrated screwed-in (TIS) abutments used in dental implants. *J Biomech.* 2005;38(1):87-97.
55. Edward, J; Charles, MR. *Mechanical Engineering Design.* McGraw-Hill Book Company. 2008;8th Ed: 1059p.

56. Al-Nsour MM, Chan HL, Wang HL. Effect of the platform-switching technique on preservation of peri-implant marginal bone: a systematic review. *Int J Oral Maxillofac Implants*. 2012;27(1):138-45.
57. Annibali S, Bignozzi I, Cristalli MP, Graziani F, La Monaca G, Polimeni A. Peri-implant marginal bone level: a systematic review and meta-analysis of studies comparing platform switching versus conventionally restored implants. *J Clin Periodontol*. 2012;39(11):1097-113.
58. Chrcanovic BR, Albrektsson T, Wennerberg A. Platform switch and dental implants: A meta-analysis. *J Dent*. 2015;43(6):629-46.
59. Strietzel FP, Neumann K, Hertel M. Impact of platform switching on marginal peri-implant bone-level changes. A systematic review and meta-analysis. *Clin Oral Implants Res*. 2015;26(3):342-58.
60. Liu Y, Wang J. Influences of microgap and micromotion of implant-abutment interface on marginal bone loss around implant neck. *Arch Oral Biol*. 2017;83:153-160.
61. Oh TJ, Yoon J, Misch CE, Wang HL. The causes of early implant bone loss: myth or science? *J Periodontol*. 2002 Mar;73(3):322-33.
62. Sotto-Maior BS, Lima Cde A, Senna PM, Camargos Gde V, Del Bel Cury AA. Biomechanical evaluation of subcrestal dental implants with different bone anchorages. *Braz Oral Res*. 2014;28(1):1-7.
63. Berglundh T, Lindhe J. Dimension of the periimplant mucosa. Biological width revisited. *J Clin Periodontol*. 1996;23(10):971-3.
64. Galindo-Moreno P, León-Cano A, Ortega-Oller I, Monje A, Suárez F, ÓValle F, Spinato S, Catena A. Prosthetic Abutment Height is a Key Factor in Peri-implant Marginal Bone Loss. *J Dent Res*. 2014 Jul;93(7 Suppl):80S-85S.
65. Barros RR, Novaes AB Jr, Muglia VA, Iezzi G, Piattelli A. Influence of interimplant distances and placement depth on peri-implant bone remodeling of adjacent and immediately loaded Morse cone connection implants: a histomorphometric study in dogs. *Clin Oral Implants Res*. 2010 Apr 1;21(4):371-8.
66. Novaes AB Jr, Barros RR, Muglia VA, Borges GJ. Influence of interimplant distances and placement depth on papilla formation and crestal resorption: a clinical and radiographic study in dogs. *J Oral Implantol*. 2009;35(1):18-27.
67. de Siqueira RAC, Fontão FNGK, Sartori IAM, Santos PGF, Bernardes SR, Tiozzi R. Effect of different implant placement depths on crestal bone levels and soft tissue behavior: a randomized clinical trial. *Clin Oral Implants Res*. 2017;28(10):1227-1233.
68. Tatullo M, Marrelli M, Mastrangelo F, Gherlone E. Bone Inflammation, Bone Infection and Dental Implants Failure: Histological and Cytological Aspects Related to Cement Excess. *J Bone Jt Infect*. 2017;2(2):84-89.
69. Paolantonio M, Perinetti G, D'Ercole S, Graziani F, Catamo G, Sammartino G, Piccolomini R. Internal decontamination of dental implants: an in vivo randomized microbiologic 6-month trial on the effects of a chlorhexidine gel. *J Periodontol*. 2008;79(8):1419-25.

70. D'Ercole S, Tetè S, Catamo G, Sammartino G, Femminella B, Tripodi D, Spoto G, Paolantonio M. Microbiological and biochemical effectiveness of an antiseptic gel on the bacterial contamination of the inner space of dental implants: a 3-month human longitudinal study. *Int J Immunopathol Pharmacol.* 2009;22(4):1019-26.
71. Bolle C, Gustin MP, Fau D, Exbrayat P, Boivin G, Grosogeat B. Early Periimplant Tissue Healing on 1-Piece Implants With a Concave Transmucosal Design: A Histomorphometric Study in Dogs. *Implant Dent.* 2015;24(5):598-606.
72. Etter TH, Håkanson I, Lang NP, Trejo PM, Caffesse RG. Healing after standardized clinical probing of the periimplant soft tissue seal: a histomorphometric study in dogs. *Clin Oral Implants Res.* 2002;13(6):571-80.
73. Moon IS, Berglundh T, Abrahamsson I, Linder E, Lindhe J. The barrier between the keratinized mucosa and the dental implant. An experimental study in the dog. *J Clin Periodontol.* 1999;26(10):658-63.
74. Huh JB, Rhee GB, Kim YS, Jeong CM, Lee JY, Shin SW. Influence of Implant transmucosal design on early peri-implant tissue responses in beagle dogs. *Clin Oral Implants Res.* 2014;25(8):962-8.
75. Puisys A, Linkevicius T. The influence of mucosal tissue thickening on crestal bone stability around bone-level implants. A prospective controlled clinical trial. *Clin Oral Implants Res.* 2015 Feb;26(2):123-9.
76. Abrahamsson I, Berglundh T, Lindhe J. The mucosal barrier following abutment dis/reconnection. An experimental study in dogs. *J Clin Periodontol.* 1997;24(8):568-72.
77. Becker K, Mihatovic I, Golubovic V, Schwarz F. Impact of abutment material and dis-/re-connection on soft and hard tissue changes at implants with platform-switching. *J Clin Periodontol.* 2012;39(8):774-80.
78. Canullo L, Bignozzi I, Cocchetto R, Cristalli MP, Iannello G. Immediate positioning of a definitive abutment versus repeated abutment replacements in post-extractive implants: 3-year follow-up of a randomised multicentre clinical trial. *Eur J Oral Implantol.* 2010;3(4):285-96.
79. Degidi M, Nardi D, Piattelli A. One abutment at one time: non-removal of an immediate abutment and its effect on bone healing around subcrestal tapered implants. *Clin Oral Implants Res.* 2011;22(11):1303-7.
80. Grandi T, Guazzi P, Samarani R, Garuti G. Immediate positioning of definitive abutments versus repeated abutment replacements in immediately loaded implants: effects on bone healing at the 1-year follow-up of a multicentre randomised controlled trial. *Eur J Oral Implantol.* 2012;5(1):9-16.
81. Degidi M, Nardi D, Daprile G, Piattelli A. Nonremoval of immediate abutments in cases involving subcrestally placed postextractive tapered single implants: a randomized controlled clinical study. *Clin Implant Dent Relat Res.* 2014;16(6):794-805.
82. Grandi T, Guazzi P, Samarani R, Maghaireh H, Grandi G. One abutment-one time versus a provisional abutment in immediately loaded post-extractive single implants: a 1-year follow-up of a multicentre randomised controlled trial. *Eur J Oral Implantol.* 2014;7(2):141-9.

Distributed in Israel



H&A Systems
11 Tuval St.
Ramat-Gan 5252226, Israel
Phone +972 (0)3 613 87 77
www.hasystems.co.il

